

PREVALENCE OF RHINOSPORIDIOSIS IN SRIKAKULAM DISTRICTS. Krishna Kumari¹, Prasad Uma², S. Ramesh³, H. L. Vasavi⁴, K. Rajani⁵**HOW TO CITE THIS ARTICLE:**

S. Krishna Kumari, Prasad Uma, S. Ramesh, H. L. Vasavi, K. Rajani. "Prevalence of Rhinosporidiosis in Srikakulam District". Journal of Evolution of Medical and Dental Sciences 2015; Vol. 4, Issue 50, June 22; Page: 8685-8689, DOI: 10.14260/jemds/2015/1256

ABSTRACT: Rhinosporidiosis is a rare chronic granulomatous disease caused by *Rhinosporidium seeberi*. Diagnosis is made on clinicopathological features. The disease is endemic in India. In India highest number of cases are reported from southern states of Kerala and Tamil Nadu which are on either side of Western Ghats. This study was conducted to know the prevalence of this disease in Srikakulam district, Andhra Pradesh. So far there is no study which is documented from this area.

KEYWORDS: Rhinosporidiosis, Prevalence, Srikakulam district.

INTRODUCTION: *Rhinosporidium Seeberi* has worldwide distribution being more prevalent in Southern India, Srilanka and South East Asia, although cases have been reported in South America, Africa and United States.^[1,2] It generally presents as swollen, pink or red polyps in the nasal cavity or the ocular conjunctiva. Treatment is mainly surgical combined with medical therapy.

MATERIAL AND METHODS: This is a prospective study for a period of three years from January 2012 to January 2015 conducted in the department of pathology at a tertiary care Centre. The clinical data with respect to clinical presentation, age, sex, habitat, type of water used for bathing were recorded. Twenty three cases with diagnosis of Rhinosporidiosis were analyzed and results documented.

RESULTS: The commonest clinical presentation was nasal obstruction with headache 9/23(39.13%) followed by nasal obstruction, headache with bleeding in 6/23(26.08%) of cases. Lesions were more confined on the left side of the nose 16/23(69.56%). Duration of lesion was ≤ 4 months in 13/23(56.52%) of cases and ≥ 4 months in 10/23(43.47%) of cases with 2 cases presenting with destruction of the bone. On clinical examination 14/23(60.86%) presented as polyp, 9/23(39.13%) as fungating lesion. The size varied from 2 to 3cm and all of them were negative for HIV. In 20/23(86.95%) cases the clinical diagnosis offered was rhinosporidiosis except in 2 cases the diagnosis was antro choanal polyp.(Table 1) Lesions were common in the age group 11 to 30 years: 19/23(82.60%) and their profession was 15/23(65.21%) were students and 8/23(34.78%) were coolie. Male: Female ratio was 4.75: 1. Majority of the cases was from tribal area 14/23(60.56%) who used both well and pond water 20/23(86.95%) and consumed salmon fish. (Table 2)

DISCUSSION: Rhinosporidiosis was first identified in 1892. In 1900 Guillermo Seeber of Argentina described the lesion in a 19 years old farm worker who had impaired breathing due to a nasal mass. The organism causing rhinosporidiosis was initially termed as "*Coccidium seeberi*" a protozoan by Wernicke, who was Seebers teacher. Ashworth in 1923 felt that it was a fungus as its life cycle was similar to a fungus and renamed it as *Rhinosporidium Seeberi*.^[3]

The taxonomic classification of *R. Seeberi* for a long time was controversial. Recent genetic analysis of the 18 SrRNA gene in *R. Seeberi* suggests that it belongs to DRIPs clade (*Dermocystidium*,

ORIGINAL ARTICLE

rosette agent, Ichthyophomias and *P. Sorospermium*) an aquatic protistan parasite about which relatively little has been discovered.^[4,5] There is no known vector for *Rhinosporidium*. The natural host is not certain, although the recent classification of *R. Seeberi* as an aquatic protistan parasite, as well as the similarity of the organism to member of a related genes that infects salmon fish, suggest that it naturally resides in some type of fish.^[5] The disease is known to occur in several animals such as horses, dogs, cat, mules and wild ducks.^[6]

Nasal infection generally occurs after swimming or bathing in stagnant fresh water ponds, lakes or rivers that contain the organism and generally more prevalent during the winter. Eye infection believed to occur from dust or air and occur primarily during summer months. The nose and the nasopharynx are the common sites of infection, occurring in about 70% of cases. Infection of eye is seen in roughly 10% of cases. Infection of the skin, ears, genitals and rectum has been observed with the development of wart like lesions in these areas, although these sites are rarely affected.^[7]

Chandrashekarayya SH et al^[8] analyzed 17 cases of rhinosporidiosis who commonly presented with nasal obstruction, epistaxis and nasal mass. Duration of symptoms varied from 6 months to 10 years. Age of patients varied from 16 years to 52 years with male preponderance. The source of infection was pond water. In the present study the commonest clinical presentation was nasal obstruction with headache (39.13%) and unilateral lesions on left side of nose (69.56%). Duration of lesion varied from 2 months to one year. Lesions were common in the age group 11 to 30 years (82.60%) with male preponderance. Majority of the cases was from tribal area (60.56%) using both well and pond water (86.95%) and consumed salmon fish.

CONCLUSION: Rhinosporidiosis is most easily and definitively diagnosed via microscopic observation. Antimicrobial treatments have proven to be ineffective; the only treatment that is known clinically successful against rhinosporidiosis is surgical excision. Education of population residing near stagnant water that is at risk of infection should be undertaken to prevent the spread of the disease. Public projects which result in creation of standing water should be checked for *R. Seeberi* contamination and also fresh water fish. Identification of infection in a large scale should evoke effective preventive measures.

REFERENCES:

1. Mohan H, Chander J, Dhir R, Singhal U. Rhinosporidiosis in India: a case report and review of literature. *Mycoses*. May-Jun 1995; 38(5-6): 223-5.
2. Capoor MR, Khanna G, Rajni, Batra K, Nair D, Venkatchalam VP, et al. Rhinosporidiosis in Delhi, north India: case series from a non-endemic area and mini-review. *Mycopathologia*. Aug 2009; 168(2): 89-94.
3. Ashworth JH. On *Rhinosporidium seeberi* (Wernicke 1903) with special reference to its sporulation and affinities. *Trans R Soc Edinburgh*. 1923; 53: 301-342.
4. Herr RA, Ajello L, Taylor JW, Arseculeratne SN, Mendoza L. Phylogenetic analysis of *Rhinosporidium seeberi*'s 18S small-subunit ribosomal DNA groups this pathogen among members of the protocistan Mesomycetozoa clade. *J Clin Microbiol*. 1999 Sep; 37(9): 2750-4.
5. Fredricks DN, Jolley JA, Lepp PW, Kosek JC, Relman DA. *Rhinosporidium seeberi*: A human pathogen from a novel group of aquatic protistan parasites. *Emerg Infect Dis*. May-Jun 2000; 6(3): 273-82.

ORIGINAL ARTICLE

6. Arora Ritu et al."Oculosporidiosis in Northern India."Indian Pediatrics. May 2001.38(5): 540-3.
7. Das S, Kashyap B, Barua M, Gupta N, Saha R, Vaid L. Nasal rhinosporidiosis in humans: new interpretations and a review of the literature of this enigmatic disease. Med Mycol. Apr 2011; 49(3): 311-5.
8. Chandrashekharayya S. H, S. S Suligavi Sachin Chougule, S. S Doddamani. Nasal Rhinosporidiosis Revisited. Clinical Rhinology: An International Journal.2010; 3(2): 73-75.

Symptoms	Number of cases(N=23)	Percentage
Nasal obstruction	4	17.39
Nasal obstruction with bleeding	4	17.39
Nasal obstruction with headache	9	39.13
Nasal obstruction with headache and bleeding	6	26.08
Duration of lesion		
≤ 4 months	13	56.52
≥ 4 months	10	43.47
Side of lesion		
Left nostril	16	69.56
Right nostril	7	30.43
Clinical Examination		
Polyp	14	60.86
Fungating lesion	9	39.13

Table 1: Clinical features in rhinosporidiosis-23

Age distribution	Number of cases(N=23)	Percentage
1-10 years	3	13.04
11-20 years	13	56.52
21-30 years	6	26.08
31-40 years	1	4.34
Sex distribution		
Males	19	82.60
Females	4	17.39
Habitat		
Semiurban	1	4.34
Rural	8	34.78
Tribal	14	60.86
Profession		
Students	15	65.21
Coolie	8	34.78
Water source		
Well and Pond	20	86.95
Pond only	3	13.04

Table 2: Demographic parameters in rhinosporidiosis-23

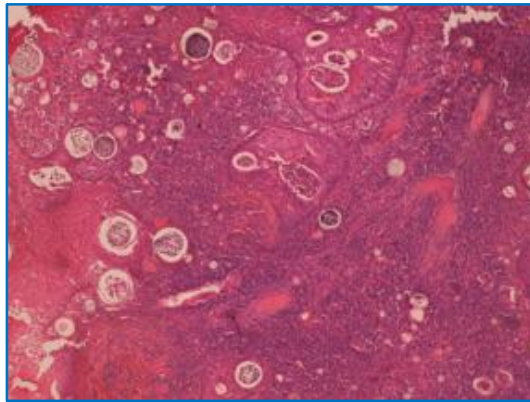


Fig. 1: Section showing squamous epithelium with multiple sporangia (H&E, 200X)

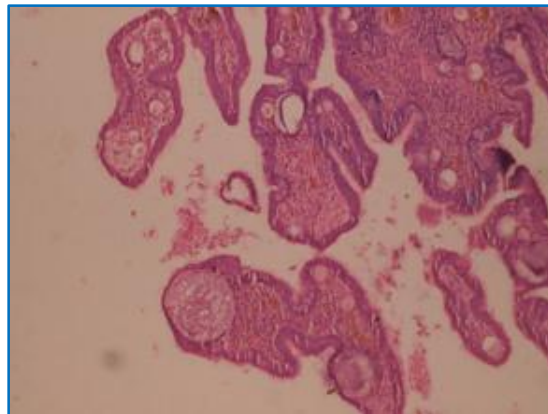


Fig. 2: Section showing pseudo stratified columnar epithelium with multiple sporangia (H&E, 200X)

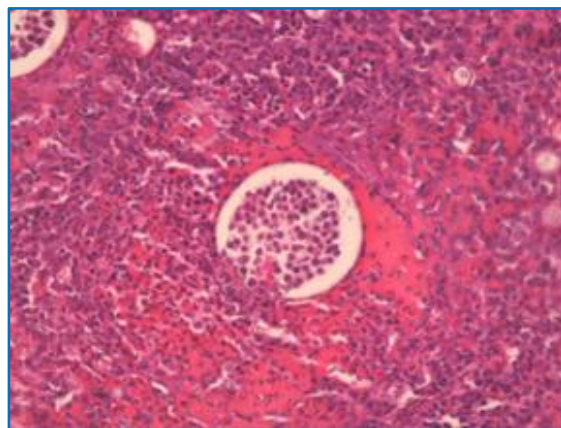


Fig. 3: Section showing sporangia with spores surrounded by chronic inflammatory cells (H&E, 400X)

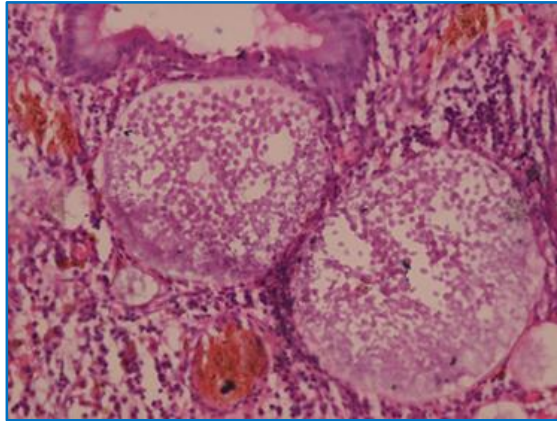


Fig. 4: Section showing sporangia with spores surrounded by chronic inflammatory cells (PAS stain 400X)

AUTHORS:

1. S. Krishna Kumari
2. Prasad Uma
3. S. Ramesh
4. H. L. Vasavi
5. K. Rajani

PARTICULARS OF CONTRIBUTORS:

1. Professor & HOD, Department of Pathology, RIMS, Srikakulam, Andhra Pradesh.
2. Associate Professor, Department of Pathology, RIMS, Srikakulam, Andhra Pradesh.
3. Assistant Professor, Department of ENT, RIMS, Srikakulam, Andhra Pradesh.

FINANCIAL OR OTHER

COMPETING INTERESTS: None

4. Assistant Professor, Department of Pathology, RIMS, Srikakulam, Andhra Pradesh.
5. Assistant Professor, Department of Pathology, RIMS, Srikakulam, Andhra Pradesh.

NAME ADDRESS EMAIL ID OF THE CORRESPONDING AUTHOR:

Dr. Prasad Uma,
Q. No. 49-3-3,
Lalithanagar,
Visakhapatnam-530016,
Andhra Pradesh.
E-mail: usha1966411@gmail.com

Date of Submission: 30/05/2015.
Date of Peer Review: 03/06/2015.
Date of Acceptance: 15/06/2015.
Date of Publishing: 19/06/2015.